



PRESENTING CLINICAL SIGNS

DATE History: Cardiac evaluation. BUN 41, Cr 2.6.

ECHOCARDIOGRAPHIC FINDINGS

6/28/22 2D, M-mode, and Doppler study.

PERFORMED BY: Left atrial size is normal. The mitral valve is normal. Left ventricular wall thickness is normal. Left ventricular internal dimensions are normal. Left ventricular systolic function is hyperdynamic. The aorta and aortic valve are normal. Right atrial and right ventricular dimensions are normal. The tricuspid valve appears normal, though very mild tricuspid regurgitation is present. The pulmonary artery and pulmonic valve are normal. No pericardial effusion or cardiac masses are seen.

Kelly Vazquez

INTERPRETED BY

Keith Blass, DVM,
MS, DACVIM
(Cardiology)

LA/Ao - 1.14
IVSd - 4.0 mm
LVPWd - 3.8 mm
LVIDd - 13.8 mm
LVIDs - 5.2 mm
FS - 62%
LVOT - 1.09 m/s
RVOT - 1.46 m/s

PATIENT

Cluney Karp

ASSESSMENT/RECOMMENDATIONS

SPECIES

Feline The only abnormality seen in this exam is very mild regurgitation of blood across Cluney's tricuspid valve. The hemodynamic effects of the regurgitation are negligible at present, and Cluney's current risk for the development of clinical signs secondary to it is very low.

BREED

No therapy is recommended based on this exam.

DLH

A recheck echocardiogram is recommended in 12 months to monitor for progression, sooner if new clinical signs compatible with cardiac dysfunction develop.

SEX

MN

AGE

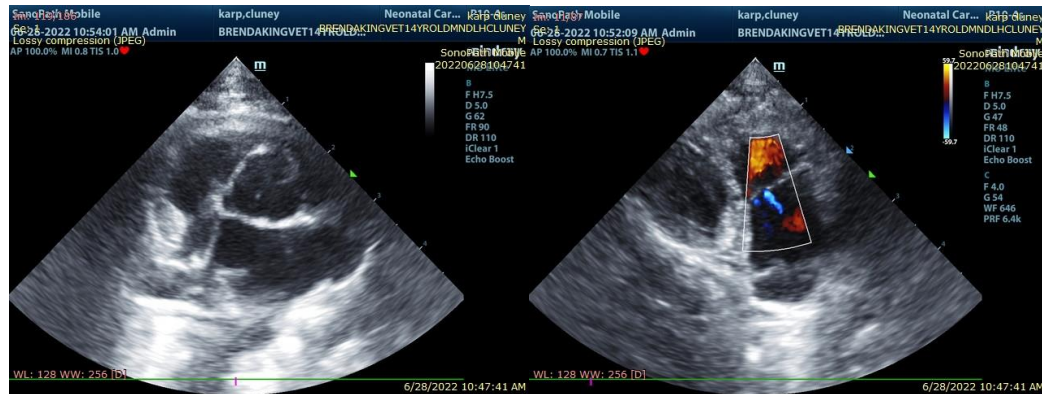
14 y

WEIGHT

7.4 lb

HOSPITAL NAME

Brenda King
Veterinary Services



The information and recommendations provided are based on the images presented by the referring veterinarian. No evaluation can be communicated regarding pathology that was not visible in the image/video clips provided.

REFERRING VET

Dr. King

Thank you for this referral. If the clinical or image interpretation does not parallel your findings or



if I can be of any further assistance please contact me.

DATE

6/28/22

Keith Blass, DVM, MS, DACVIM (Cardiology)
KeithBlass@gmail.com
631-804-5754

PERFORMED BY:

Kelly Vazquez

INTERPRETED BY

Keith Blass, DVM,
MS, DACVIM
(Cardiology)

PATIENT

Cluney Karp

SPECIES

Feline

BREED

DLH

SEX

MN

AGE

14 y

WEIGHT

7.4 lb

HOSPITAL NAME

Brenda King
Veterinary Services

REFERRING VET

Dr. King